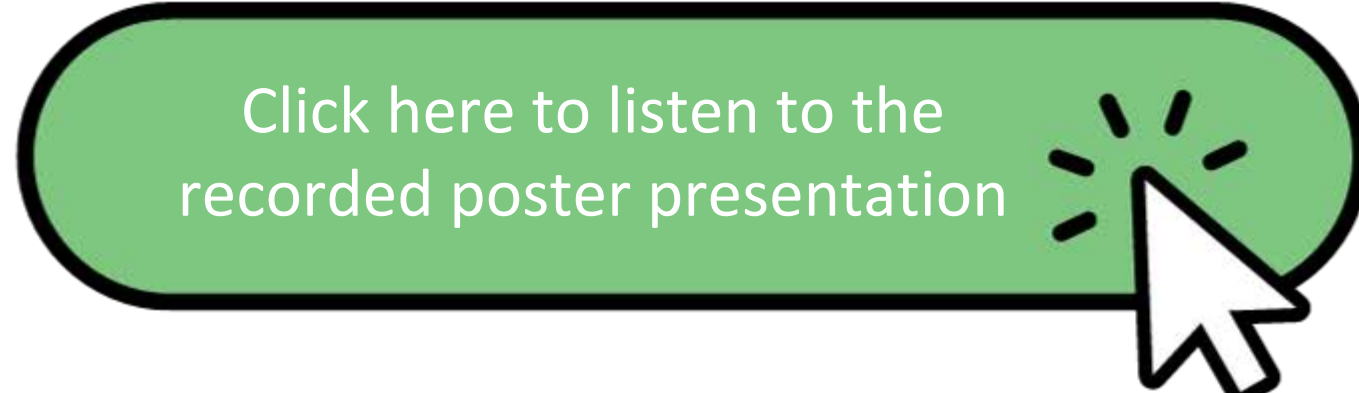


# Understanding Species Variation in the Occurrence of Spontaneous Background Eye Lesions in Toxicology Studies: A Comparative Study

Nirmala Chinnappareddy<sup>1</sup>, Amanda Hunerdosse<sup>1</sup>, Julie Forget<sup>1</sup>, Simone Iwabe<sup>2</sup> and Norbert Makori<sup>1</sup>

<sup>1</sup>Altasciences Preclinical Seattle LLC, Seattle, WA, United States, <sup>2</sup>Altasciences Preclinical Scranton, Scott Township, PA, United States



## ABSTRACT

Detailed ophthalmic examinations performed prior to test article administration are crucial for screening background lesions and for comparing and deriving conclusions of the potential test article-induced ocular toxicity. We reviewed the acclimation or pre-test data collected at our facility for commonly observed ocular lesions in rats, mice, non-human primates (NHPs), and dogs for the past one year.

**Rats:** A total of 930 animals (465/sex) were examined of which 19.57% had background findings (cataract: 67.58%, corneal dystrophy: 30.22%, others 2.20%). Male and female animals had a comparable prevalence rate of 19.35% and 19.78%, respectively.

**Mice:** A total of 690 mice (346 males and 344 females) were examined of which 11.01% had background lesions (cataract: 78.95%, retinopathy: 11.84%, corneal dystrophy: 5.26%, others 3.95%). Male and female animals had a comparable prevalence rate of 11.27% and 10.76% respectively.

**NHPs:** A total of 599 animals (300 males and 299 females) were examined of which 8.01% had background lesions (cataract: 56.25%, bilateral optic atrophy: 12.50%, optic disc variants: 10.42%, retinopathy: 2.08%, others: 10.42%). Males had more background findings (13.65%) compared to females (5.62%).

**Dogs:** A total of 162 dogs (81/sex) were examined of which 9.26% had background lesions (cataract: 53.33%, corneal dystrophy: 13.33%, retinopathy: 12.5%, others 20.00%). Male and female animals had a comparable prevalence rate of 9.88% and 8.64% respectively.

It is recommended either to allocate an animal with findings to a control group or to exclude it from the study depending on the severity of background lesions.

## INTRODUCTION

The eye is a prime target for various systemic toxicities due to its large blood flow to organ weight. Due to the transparent nature of the eye, ophthalmic examinations can be performed while in life to visualize any changes to arteries, veins, and neural tissue readily detectable. Thus, used in combination with clinical observations, clinical pathology, and histopathology provides valuable information when assessing potential toxicity of a test article. However, differences in ocular anatomy and physiology in commonly used species in toxicology studies may alter the way a drug interacts with the eye, whether administered locally or systemically. Therefore, it is important to understand these species differences, commonly occurring spontaneous background lesions, and how they can influence the outcome and interpretation of safety or efficacy data for therapeutics.

The purpose of this study was to investigate commonly occurring spontaneous background eye lesions in rats, mice, NHPs, and dogs and to compare the prevalence between male and female animals. In this study, we reviewed the acclimation data collected from studies conducted at our facility between 2022 and 2023.

## MATERIALS AND METHODS

Table 1. Test system

	Rats	Mice	NHPs	Dogs
Number of studies screened	8	5	15	6
Species/strain	<i>Rattus norvegicus</i> Sprague Dawley	<i>Mus musculus</i> CD-1	<i>Macaca fascicularis</i> Cynomolgus	<i>Canis lupus</i> Beagle
Age	8 - 12 weeks	8-12 weeks	2 - 4 years	6 - 12 months
Body weight	100 - 400 g	20 - 45 g	1.6 - 3 kg	6 - 10 kg
Total Animals Screened	465 M, 465 F	346 M, 346 F	300 M, 299 F	81 M, 81 F

All animal-related procedures were approved by Altasciences IACUC.



Figure 1. Indirect ophthalmoscope



Figure 2. Slit lamp biomicroscope

## RESULTS AND DISCUSSION

Table 2. Common background eye lesions observed in Rats, Mice, NHPs and Dogs

	Rats		Mice		NHPs		Dogs	
	Male	Female	Male	Female	Male	Female	Male	Female
Total Animals Screened	465	465	346	344	300	299	81	81
Cataract	57	66	29	31	19	8	6	2
Corneal Dystrophy	33	22	1	3	-	-	2	0
Retinopathy	-	-	6	3	1	0	0	1
BOA	-	-	-	-	3	3	-	-
Iris nevus	-	-	-	-	4	0	-	-
Optic disc variants	-	-	-	-	3	2	-	-
Other	0	4	3	0	4	1	0	3
Lesions Incidence (total)	90	92	39	37	34	14	8	6

-: Not applicable, BOA: bilateral optic atrophy, Other: scleral crescent at temporal edge of optic disk, persistent hyaloid artery anterior to optic disc, retinal striae, iridocyclitis, vitreous hemorrhage, corneal ulcers etc.

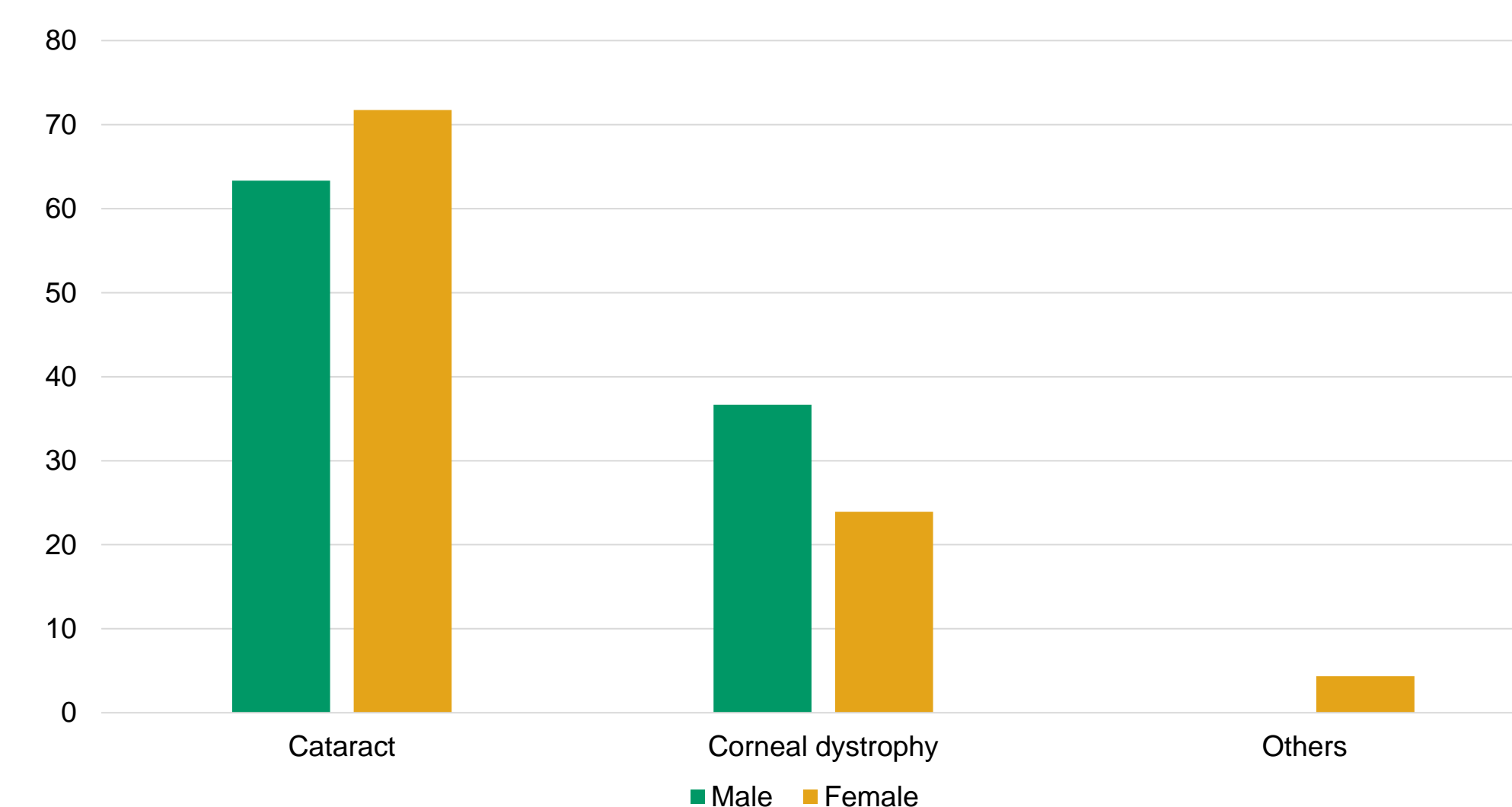


Figure 3. Spontaneous background eye lesions in rats

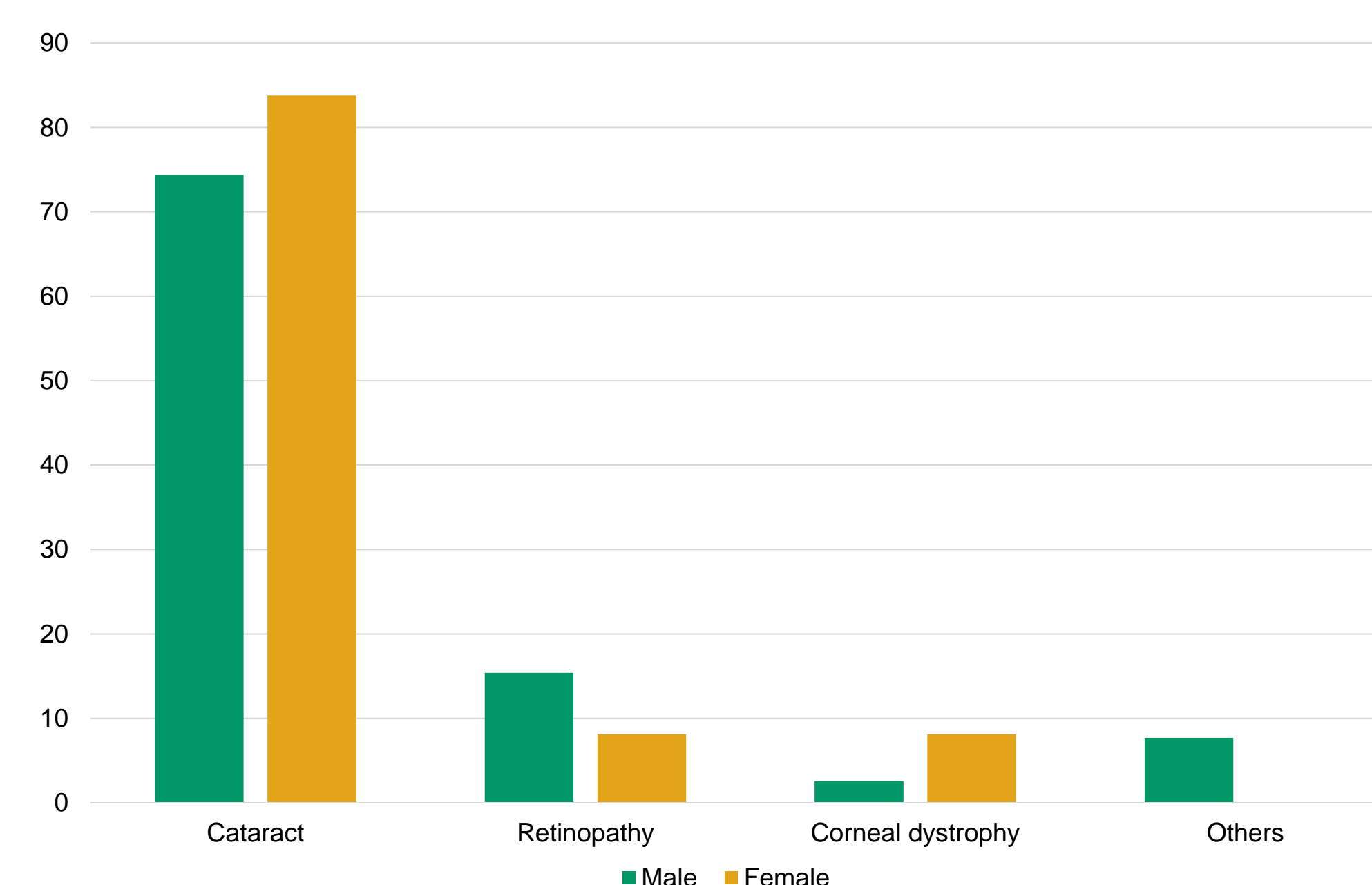


Figure 4. Spontaneous background eye lesions in mice

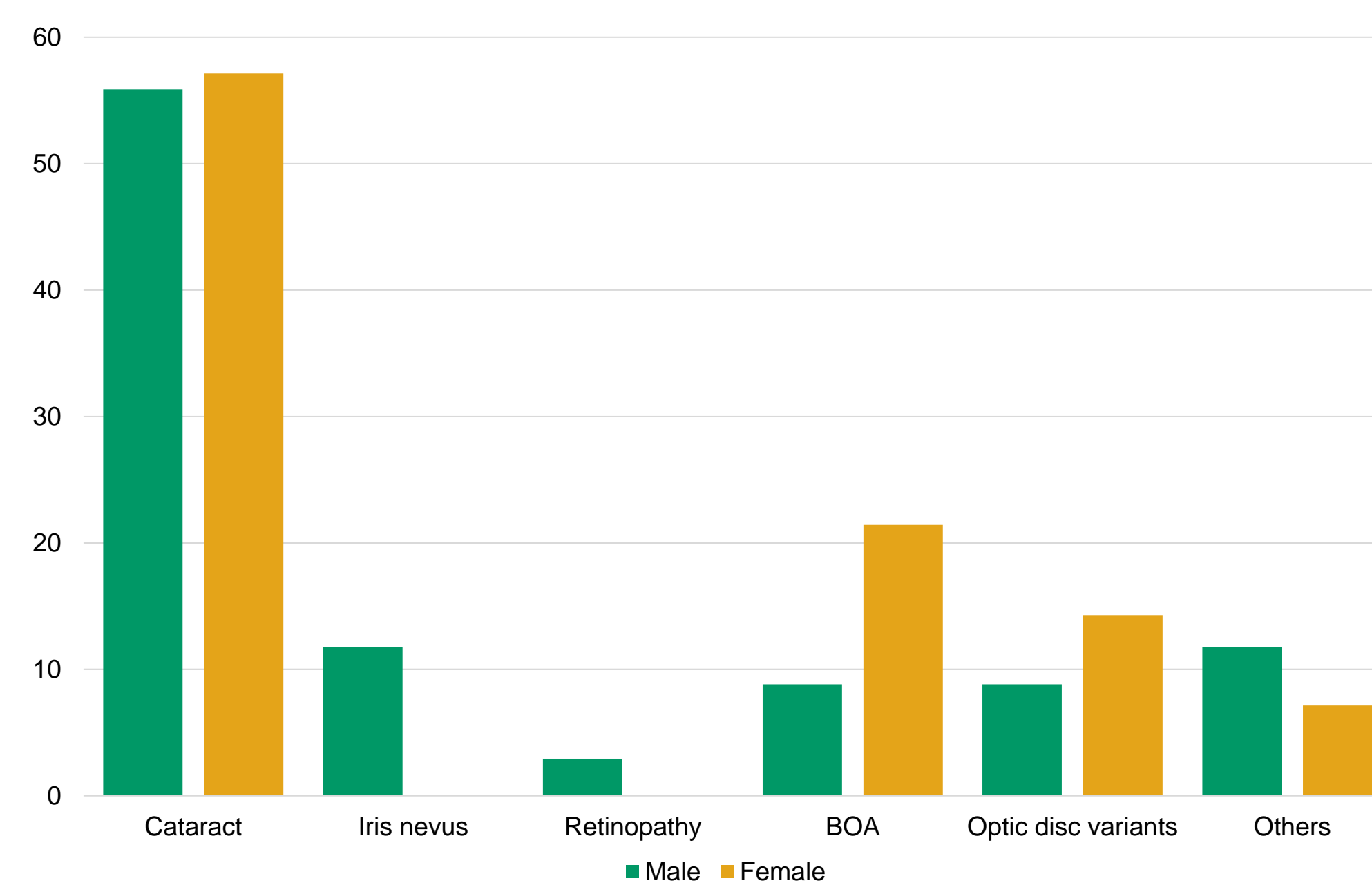


Figure 5. Spontaneous background eye lesions in NHPs

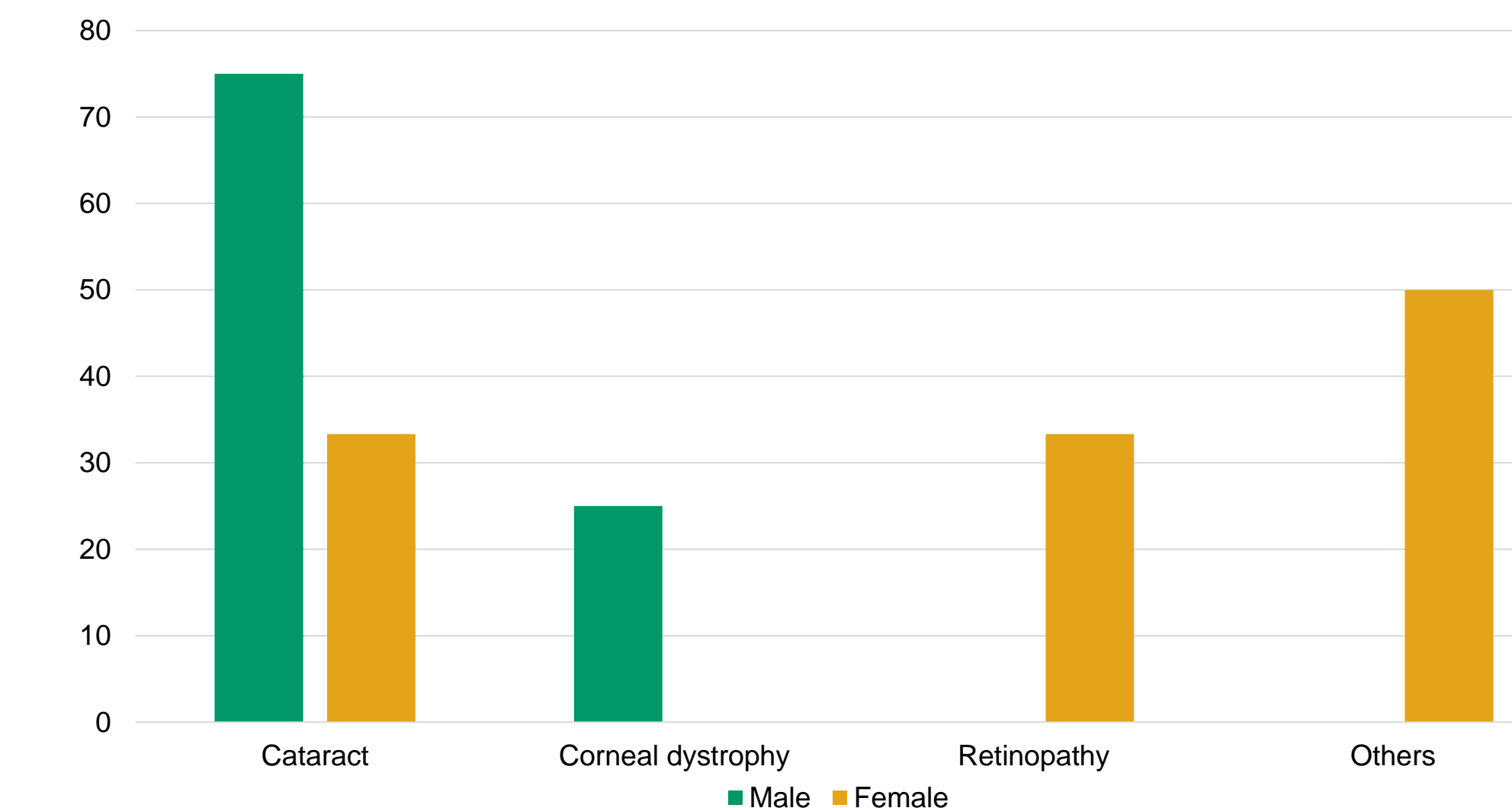


Figure 6. Spontaneous background eye lesions in dogs

## CONCLUSION

From this study, it was concluded that the occurrence of spontaneous background eye lesions varies between species. There were no sex differences noticed within the same species except for NHPs where male animals had more background lesions compared to females. Among all the background lesions diagnosed, cataract was the most common finding followed by corneal dystrophy in rats and dogs, retinopathy in mice, and bilateral optic atrophy and optic disc variants in NHPs.

Acclimation or pre-test eye examinations help to eliminate those animals not suitable for inclusion in the study and to establish a baseline to compare and understand the progression of findings. Any animal with findings can either be excluded from the study if findings are severe or allocated to the control group if minor based on the diagnosis of a board-certified veterinary ophthalmologist. Animals should be examined prior to dose administration and end of the dosing period, and possibly during the recovery phase depending on the study duration and design. The findings should be interpreted considering the pre-test data, species-specific background lesions, nature of the test article and correlation with other in-life data for the group.

## REFERENCES

David W (2014), The Ophthalmic Examination as It Pertains to General Ocular Toxicology: Basic and Advanced Techniques and Species-Associated Findings. Methods in Pharmacology and Toxicology, pp 143-203.  
Munger R J, Collins M (2013) Assessing ocular toxicity potential: basic theory and techniques. In: Weir A B, Collins M (eds) Molecular and integrative toxicology: assessing ocular toxicology in laboratory animals. Humana, New York, pp 23-52.  
Brian C G, Eva A, and Jacklyn H S (2014). Selection of Appropriate Animal Models in Ocular Research: Ocular Anatomy and Physiology of Common Animal Models. In: Brian C G (ed) Methods in Pharmacology and Toxicology, Humana, New York, pp 7-32.